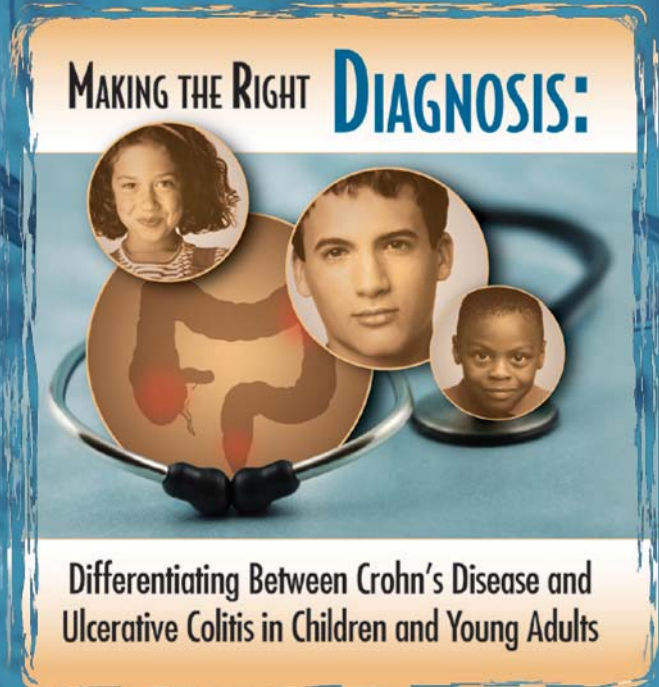


## A Case-Based Monograph Focusing on Pediatric IBD



## A Case-Based Monograph Focusing on Pediatric IBD

### Chair

**Athos Bousvaros, MD, MPH**  
Associate Professor of Pediatrics  
Harvard Medical School  
Boston, MA

### Faculty

**Jeffrey Goldsmith, MD**  
Assistant Professor of Pathology  
Harvard Medical School  
Boston, MA

**Jennifer Strople, MD, MS**  
Assistant Professor of Pediatrics  
Feinberg School of Medicine  
Northwestern University  
Chicago, IL

### Medical Writer

**Jason Jenkins**  
TCL Institute, LLC  
Cary, NC

**LeAnne Vitito, MS, RN, FNP-BC, CGRN**  
Department of Pediatric Gastroenterology  
University of Nebraska Medical Center  
Omaha, NE

Release Date: May 13, 2009 Expiration Date: May 12, 2011

Estimated time to complete: 2.0 hours

Jointly sponsored by NASPGHAN, CDHNF, and TCL Institute, LLC.

This educational activity is supported by an independent medical education grant from Centocor, Inc. and Shire.

## Introduction

Although they represent 2 unique idiopathic inflammatory disorders under the umbrella term inflammatory bowel disease (IBD), the signs and symptoms for pediatric Crohn's disease (CD) and ulcerative colitis (UC) are similar. Multiple interpretations of the criteria for UC, CD, and IBD-unclassified (also known as "indeterminate colitis") among experts pose an obstacle to accurate diagnosis. The lack of consensus also obstructs the design and interpretation of clinical trials; most trials restrict entry to 1 disease, and pediatric patients with IBD-unclassified are frequently excluded.

While refinements in classification criteria have led to clearer definitions of CD and UC, researchers and clinicians still face challenges classifying certain patients. This monograph presents the latest histologic and endoscopic criteria for IBD to help clinicians categorize patients. By investigating 3 realistic clinical vignettes, pediatric gastroenterologists will learn the keys to distinguishing acute self-limited colitis (ASLC) from IBD, differentiating UC from CD in children, and approaching patients with IBD-unclassified. This monograph will also elucidate the meanings of "backwash ileitis," "indeterminate colitis," and other terms that have caused misunderstanding among clinicians, thus enabling them to "speak the same language" and subtype patients more accurately.

## Target Audience

This activity is designed for gastroenterologists, physician assistants, nurse practitioners, and other clinicians with an interest in the diagnosis and treatment of pediatric bowel conditions.

## Learning Objectives:

Upon completion of this activity, participants should be able to:

- Render accurate diagnoses based on identifying the range of histological features and endoscopic findings of pediatric UC and CD
- Differentiate pediatric IBD from ASLC
- Apply consistent classification and diagnostic criteria to more accurately phenotype pediatric IBD patients
- Implement a systematic approach to diagnosis and management based upon a standard algorithm
- Delineate the features of IBD-unclassified and how to follow up these cases

## Physicians

This activity has been planned and implemented in accordance with the Essential Areas and policies of the Accreditation Council for Continuing Medical Education (ACCME) through the joint sponsorship of the North American Society for Pediatric Gastroenterology, Hepatology & Nutrition (NASPGHAN), the Children's Digestive Health and Nutrition Foundation (CDHNF), and TCL Institute, LLC. NASPGHAN is accredited by the ACCME to provide continuing medical education for physicians.

## AMA PRA Statement

NASPGHAN designates this educational activity for a maximum of 2.0 *AMA PRA Category 1 Credit(s)*<sup>™</sup>. Physicians should only claim credit commensurate with the extent of their participation in the activity.

## Statement of Disclosure

All faculty/speakers, planners, abstract reviewers, moderators, authors, coauthors, and administrative staff participating in the continuing medical education programs sponsored by NASPGHAN, CDHNF, and TCL Institute, LLC are expected to disclose to the program audience any/all relevant financial relationships related to the content of their presentation(s).

Accordingly, the staff at NASPGHAN, CDHNF, and TCL Institute, LLC have reported no financial relationships with any commercial interests related to the content of this educational activity.

Dr. Goldsmith, Dr. Strople, and Ms. Viitio have nothing to disclose.

Dr. Bousvaros reported that he receives research support from Abbott Laboratories and Merck & Co., Inc. and is a speaker for Abbott Laboratories.

In accordance with ACCME Standards for Commercial Support of CME, NASPGHAN, CDHNF, and TCL Institute, LLC implemented mechanisms to identify and resolve conflicts of interest for all individuals in a position to control content of this CME activity. To resolve identified conflicts of interest, the educational content was peer-reviewed by a physician member of the NASPGHAN Review Committee who has nothing to disclose. The resulting certified activity was found to provide educational content that is current, evidence based, and commercially balanced.

## Disclosure of Unlabeled or Investigational Drugs

This educational activity may contain discussion of published and/or investigational uses of agents that are not indicated by the FDA. The opinions expressed in the educational activity are those of the faculty. Please refer to the official prescribing information for each product for discussion of approved indications, contraindications, and warnings. Further, attendees/participants should appraise the information presented critically and are encouraged to consult appropriate resources for any product or device mentioned in this program.

## Medium or Combination of Media Used

This activity will consist of a mailed and Web-based monograph and a posttest. To view a pdf of the monograph please visit <http://www.totalmeded.com/enduring/monographs/ibdclassification>. This activity requires Adobe Acrobat to view a pdf of the monograph. If you encounter problems, please notify us at [questions@TotalMedEd.com](mailto:questions@TotalMedEd.com).

## How to Receive CME Credit:

To receive CME credit for reviewing "Making the Right Diagnosis: Differentiating Between Crohn's Disease and Ulcerative Colitis in Children and Young Adults", participants must review the CME information (learning objectives, disclosures, etc), review the entire activity, and complete the activity posttest and evaluation questions.

To complete the activity posttest and evaluation, please visit: [http://www.gotomylist.com/evaluator/evaluation\\_start.cfm?pk\\_event=271](http://www.gotomylist.com/evaluator/evaluation_start.cfm?pk_event=271). Certificates will be provided immediately after completion of both posttest and evaluation.

Questions about receiving credit: Please e-mail [Katie@cmehelp.com](mailto:Katie@cmehelp.com)

## Provider Contact Information

Jointly sponsored by NASPGHAN, CDHNF, and TCL Institute, LLC.  
For questions, please contact:

TCL Institute, LLC | 104 Towerview Court | Cary, NC 27513  
Phone: 919-467-0006 ext. 233 | Fax: 215-243-7273

## Disclaimer

The content and views presented in this educational activity are those of the authors and do not necessarily reflect those of NASPGHAN, CDHNF, TCL Institute, LLC, Centocor, Inc., or Shire. This material is prepared based upon a review of multiple sources of information, but it is not exhaustive of the subject matter. Therefore, health care professionals and other individuals should review and consider other publications and materials on the subject matter before relying solely upon the information contained within this educational activity.

## Policy on Privacy and Confidentiality

NASPGHAN, CDHNF, and TCL Institute, LLC will make every effort to protect the privacy of every individual participant of this activity and will use information gathered only to maintain records as required by the American Medical Association (AMA) and ACCME.

This activity does not require readers to "register" to review the material with the exception of physicians and other health care providers who desire to receive CME credit for this accredited activity. If an individual completes a CME for this accredited activity, we are required by the AMA and ACCME to collect personal information on the individual, such as their name, address, and phone number, that will allow us to issue a CME certificate to them and to keep this information on file for up to 6 years.

Personal information gathered will not be released to any other company or organization for any purpose. This information remains totally confidential. If you have any questions about TotalMedEd.com or any of our policies, you may contact us at [help@TotalMedEd.com](mailto:help@TotalMedEd.com).

© Copyright 2009 NASPGHAN, CDHNF, and TCL Institute, LLC.

## Introduction

Inflammatory bowel disease (IBD) is a general term encompassing a range of diseases that cause chronic inflammation in the gastrointestinal tract and are not due to infections or other identifiable causes.<sup>1</sup> The 2 main types of IBD are Crohn's disease (CD) and ulcerative colitis (UC).

The Crohn's and Colitis Foundation of America estimates that as many as 1 million Americans have either CD or UC.<sup>2</sup> Of these individuals, approximately 20% are diagnosed in childhood (under 20 years old).<sup>3</sup> The incidence and prevalence of CD and UC are comparable.<sup>2</sup> Most pediatric epidemiologic studies show an increased incidence of CD compared to UC<sup>3</sup>; in children aged 3-5 years, UC is more common than CD.<sup>4</sup>

While pediatric CD and UC represent 2 unique idiopathic inflammatory disorders, their signs and symptoms are similar.<sup>1</sup> CD is a transmural inflammatory condition that may involve any site in the gastrointestinal tract (panenteric), but most commonly involves the terminal ileum, ascending colon, and perianal regions.<sup>1,5</sup> In contrast, classic UC is an inflammatory condition limited to the mucosal layer of the colon. In a subset of patients with IBD involving the colon, clinicians may have difficulty categorizing the illness as either CD or UC. In these patients, the terms "indeterminate colitis" or "IBD-unclassified" are utilized.

IBD manifests clinically and subclinically in many ways. Researchers are arriving at the consensus that what are called CD and UC are actually groups of disorders with a variety of underlying mechanisms with similar clinical manifestations.<sup>6</sup> Clinicians sometimes have difficulty differentiating the 2 diseases and may misclassify UC as CD, CD as UC, or overuse the term "indeterminate colitis."<sup>5</sup> This uncertainty has been estimated to occur in 5% to 20% of pediatric patients, and clinicians may diagnose these patients as having "IBD-unclassified" (also known as "indeterminate colitis").<sup>1,3</sup>

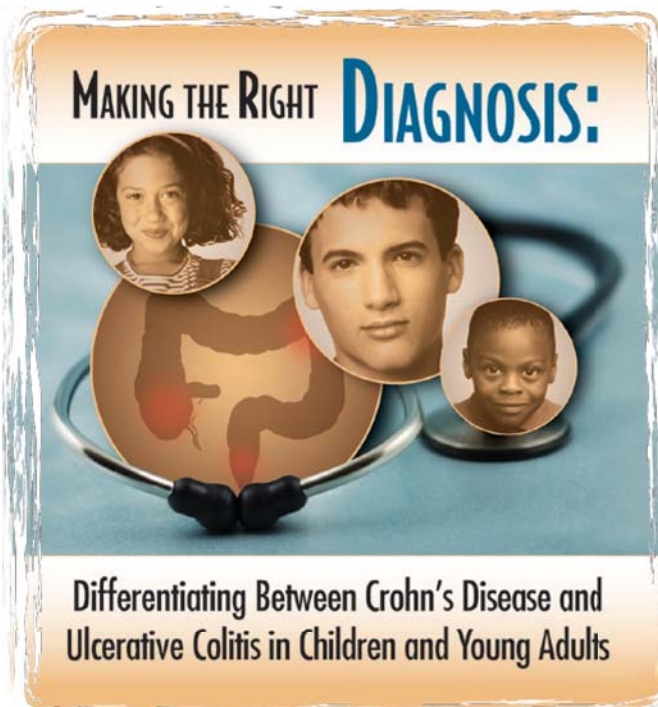
Accurate classification of IBD as either UC or CD may have several benefits, including<sup>5,7</sup>:

- Permitting clinicians to clearly discuss diagnosis and treatment options with patients and their families
- Assessing disease prognosis
- Facilitating the conduct of epidemiologic studies in children
- Allowing the entry of children into clinical trials of emerging therapies
- Enabling improved genetic research
- Allowing for more disease-specific drug therapy
- Helping determine whether or not surgery is indicated
- Facilitating International Classification of Diseases-9 coding
- Facilitating letters of medical necessity to insurance companies

These factors underscore the importance of accurate classifications and definitions of the various diseases associated with IBD. Nevertheless, there is a lack of agreement and consensus among experts as to the criteria for diagnosing UC, CD, and IBD-unclassified. Furthermore, a variety of knowledge gaps exist regarding the phenotyping of pediatric IBD, challenging clinicians who diagnose and treat pediatric IBD patients. This educational activity documents these gaps and proposes teaching approaches to address clinicians' educational needs.

## Pathogenesis of IBD Is Believed to Involve a Combination of Factors

Although considerable progress has been made in IBD research, investigators do not yet know what causes the disease.<sup>2</sup> As in adults, the prevailing hypothesis in pediatric IBD is that intestinal inflammation is the result of a complex interaction of genetic, environmental, and immune factors.<sup>8</sup>



The basis for the genetic role in IBD pathogenesis is that the disease usually runs in families.<sup>2</sup> About 20% to 25% of patients may have a close relative with either CD or UC. If a person has a first-degree relative with the disease, his or her risk of developing IBD is about 10 times greater than that of the general population. If that relative happens to be a sibling, the risk is 30 times greater.

Many genes may play a role in determining the risk of developing IBD. These genes include the *NOD2/CARD15* gene (which was the first gene shown to increase the risk of developing CD), the interleukin-23 receptor gene, and the *ATG16L1* (autophagy) gene.<sup>9,10</sup> Several other genes (*IBD5*, *DLG5*, *IBD3*, *MDR1*) have been identified as factors in the pathogenesis of IBD and are currently being elucidated.<sup>9,11</sup> Loci on chromosome 20 q13 and 21 q22 in regions of *TNFRSF6B* and *PSMG1* genes in pediatric patients have recently been identified and are currently under investigation.

No one environmental agent has been proven to be an etiologic factor for IBD.<sup>9</sup> There is likely no single microbiologic organism that causes IBD in humans. However, genetically predisposed animals generally

do not develop IBD unless they are exposed to intestinal bacteria.<sup>12</sup> Studies are currently underway to determine the role of intestinal microflora as a cause of IBD.<sup>9</sup>

Certain diets may increase or decrease the risk of IBD, but no one specific diet has been demonstrated to be causative or protective.<sup>13</sup> Tobacco use has been identified as a risk factor for adult CD and a protective factor for adult UC, but its role in pediatric IBD is obviously limited. Other environmental factors that have been investigated include breastfeeding, occupation, education, climate, stress, and nonsteroidal anti-inflammatory drug (NSAID) exposure. However, no clear association between these factors and IBD has been demonstrated. While IBD can occur in any country, countries in northern climates that are more developed (eg, United States, Canada, and those in northern Europe) have a higher prevalence of IBD.<sup>2</sup>

## IBD Classification Systems: A Historical Overview

### Diagnostic Schema Through the Years

The definitions of CD and UC have varied in the literature, leading to the potential for different outcomes in epidemiologic studies.<sup>3,14-16</sup> Therefore, consensus groups of IBD experts have developed both definitions and classification modules for CD and UC.

The Vienna Working Party developed one of the first international classification systems in 1998 that was based on 3 elements<sup>17</sup>:

- Age of onset (< 40 years or ≥ 40 years)
- Disease location (terminal ileum, ileocolon, colon, or upper gastrointestinal)
- Disease behavior (nonstricturing nonpenetrating, stricturing, or penetrating)

The Montreal Working Party at the World Congress of Gastroenterology expanded upon the Vienna scheme in 2005.<sup>7</sup> For classifying patients with UC, the Montreal Working Party implemented 2 criteria: disease extent and activity. Disease extent was subdivided into 3 categories: ulcerative proctitis limited to the rectum, left-sided ulcerative colitis, and extensive ulcerative colitis. Disease activity was categorized as remission, mild, moderate, and severe. For patients with CD, the Montreal Working Party classified patients according to 3 criteria: age of onset, disease location, and disease behavior, as shown in **Table 1**. The Montreal Working Party categorized disease locations as ileal, colonic, ileocolonic, and isolated upper gastrointestinal disease. The Montreal Working Party also added perianal disease as a separate subclassification in the disease behavior category because perianal fistulizing disease is not necessarily associated with intestinal fistulizing disease.<sup>7,18</sup>

**Table 1. Vienna and Montreal Classification for CD<sup>7</sup>**

	Vienna	Montreal
Age at Diagnosis	<ul style="list-style-type: none"> <li>Below 40 years</li> <li>Above 40 years</li> </ul>	<ul style="list-style-type: none"> <li>Below 16 years</li> <li>Between 17 and 40 years</li> <li>Above 40 years</li> </ul>
Location	<ul style="list-style-type: none"> <li>Ileal</li> <li>Colonic</li> <li>Ileocolonic</li> <li>Upper</li> </ul>	<ul style="list-style-type: none"> <li>Ileal</li> <li>Colonic</li> <li>Ileocolonic</li> <li>Isolated upper disease*</li> </ul>
Behavior	<ul style="list-style-type: none"> <li>Nonstricturing, nonpenetrating</li> <li>Stricturing</li> <li>Penetrating</li> </ul>	<ul style="list-style-type: none"> <li>Nonstricturing, nonpenetrating</li> <li>Stricturing</li> <li>Penetrating</li> <li>(Perianal disease modifier)<sup>†</sup></li> </ul>

\* "Isolated upper disease" is a modifier that can be added to ileal, colonic, and ileocolonic when concomitant upper gastrointestinal disease is present.  
<sup>†</sup> "Perianal disease" is added to nonstricturing, nonpenetrating; stricturing; and penetrating when concomitant perianal disease is present.

In 2005, a consensus group of pediatric gastroenterologists from Europe met in Porto, Portugal and published a paper outlining the initial diagnostic evaluation of a child with suspected IBD.<sup>19</sup> The group outlined characteristics on endoscopy and histology that may differentiate CD and UC, as shown in **Table 2**. The Porto Group recommended small bowel radiography, upper endoscopy, colonoscopy, ileoscopy, and biopsies as part of the initial workup of a child with IBD.

**Table 2. Endoscopy and Histology in IBD<sup>19</sup>**

	CD	UC
Endoscopy (and visualization of oral and/or perianal regions)	<ul style="list-style-type: none"> <li>Ulcers (aphthous, linear, or stellate)</li> <li>Cobblestoning</li> <li>Skip lesions</li> <li>Strictures</li> <li>Fistula</li> <li>Abnormalities in oral and/or perianal regions</li> <li>Segmental distribution</li> </ul>	<ul style="list-style-type: none"> <li>Ulcers</li> <li>Erythema</li> <li>Loss of vascular pattern granularity</li> <li>Friability</li> <li>Spontaneous bleeding</li> <li>Pseudopolyps</li> <li>Continuous with variable proximal extension from rectum</li> </ul>
Histology	<ul style="list-style-type: none"> <li>Submucosal (biopsy with sufficient submucosal tissue) or transmural involvement (surgical specimen)</li> <li>Ulcers, crypt distortion</li> <li>Crypt abscess</li> <li>Granulomas (noncaseating, nonmucin)</li> <li>Focal changes (within biopsy)</li> <li>Patchy distribution (biopsies)</li> </ul>	<ul style="list-style-type: none"> <li>Mucosal involvement</li> <li>Crypt distortion</li> <li>Crypt abscess</li> <li>Goblet cell depletion</li> <li>Mucin granulomas (rare)</li> <li>Continuous distribution</li> </ul>

While refinements in classification criteria have led to clearer definitions of CD and UC, researchers and clinicians still face challenges classifying certain patients. This monograph investigates cases in which clinicians may find it difficult to discern acute self-limited colitis (ASLC) from IBD, or differentiate UC from CD.

### Why Is it Important to Properly Classify Patients as Having CD, UC, or "IBD-Unclassified"?

Some medications that are effective in CD have not yielded efficacy in UC (eg, methotrexate), and some medications that treat UC patients may provide limited benefits to CD patients (eg, aminosaliclates).<sup>20</sup> Although biologics such as infliximab have yielded efficacy in maintaining disease remission in CD, patients with UC are generally less likely to respond and their efficacy in patients with IBD-unclassified have not yet been established.<sup>21</sup>

In addition, surgical treatments vary between the 2 diseases.<sup>22</sup> For example, ileoanal pouch anastomosis (IPAA) is the standard surgery for a child with UC, but IPAA may have severe complications if performed in a child with CD. Given these differences and that the 2 illnesses have different outcomes, making an accurate diagnosis enables clinicians to more clearly communicate prognoses and treatment plans to the patient and family.<sup>5</sup>

Accurate diagnosis is also crucial for research purposes.<sup>5</sup> Rendering a diagnosis of CD or UC is essential if a patient is to be enrolled in a clinical trial or an epidemiologic study. Most clinical trials restrict entry to 1 disease (UC or CD), and patients with IBD-unclassified are usually excluded from such trials. Since an expanding number of new treatments for IBD are being evaluated in children, excluding children from such trials will be to their detriment. In addition, the cornerstone of genetic studies is having an accurate phenotypic diagnosis, and misclassifying a child could lead to false results.

Making a comfortable diagnosis of either CD or UC can be challenging in some children, and clinicians may be tempted to label a large number of colitis patients as IBD-unclassified.<sup>5</sup> However, overusing the "IBD-unclassified" diagnosis may result in an inappropriate therapeutic strategy (eg, delay of surgery) and uncertainty concerning long-term prognosis (eg, permanent ostomy or ileoanal anastomosis vs IPAA). The prognosis in patients with IBD-unclassified is worse than in patients with UC due to a higher frequency of relapse and an increased risk of colon cancer.<sup>23</sup> Furthermore, patients with true IBD-unclassified are more likely to undergo colectomy, and pouch failure rates are much higher in this population than in patients with definite UC.

### Why Is it Difficult to Make a Definitive Diagnosis of UC or CD?

#### Reasons Why an Accurate Diagnosis Can Be Difficult<sup>5</sup>

- CD can be limited to the colon
- Interobserver variability between endoscopists and pathologists
- Patients with UC may have nonclassical features that suggest another diagnosis (eg, gastritis, backwash ileitis, patchy disease)
- The disease appearance can change over time or with medical therapy

Making a comfortable diagnosis of either CD or UC can be challenging in some children. In many patients with CD, especially those with ileal or ileocecal disease, making the diagnosis of CD is straightforward.<sup>5</sup> Difficulties arise, however, in patients whose disease is largely limited to the colon. Here, clinicians rely upon the endoscopic appearance of the bowel and the findings on histology.

Unfortunately, a poor initial description of endoscopic findings combined with interobserver variation may contribute to classification uncertainty.<sup>24</sup> Some pathologists are more sensitive to features that might be found in CD. Other pathologists are more prepared to accept a larger range of changes in UC, thereby diminishing the number of patients with IBD-unclassified or CD. Theodossi and colleagues revealed that the range of agreement in 10 observers with a special interest in gastrointestinal pathology was wide.<sup>25</sup> The 10 observers who studied the exact same biopsy specimens to ascertain whether they indicated UC or CD disagreed from 25% to 35% of the time.

Even with accurate endoscopic and pathologic descriptions at time of initial assessment, there may be some atypical clinical and endoscopic features that make classification more challenging. Children with new onset UC may have "nonclassical findings," including gastritis, cecal patch, microscopic ileitis, patchiness, or relative rectal sparing.<sup>5</sup>

Data presented in this monograph will explain the significance (or lack thereof) of these findings. The following clinical vignettes provide an overview of how to differentiate ASLC from IBD, how to distinguish between UC and CD in children, and how to approach patients with IBD-unclassified.

### Case 1 Presentation: Differentiating Acute Self-limited Colitis (ASLC) From IBD



Michelle, a 12-year-old female with a 2-week history of bloody diarrhea, presents to you for evaluation. Cultures for *Salmonella*, *Campylobacter*, *Shigella*, *Clostridium difficile*, and *Yersinia* are all negative. The diarrhea and bloody stools have decreased in severity, but are still ongoing. You are not sure whether Michelle has infectious colitis, self-limited colitis, or IBD. Therefore, you decide to perform an endoscopy and colonoscopy with biopsies.

## Presenting Symptoms of Pediatric IBD

The evaluation of a child with suspected IBD involves history taking, physical examination, laboratory investigations, endoscopy with biopsies, and radiology.<sup>19</sup> **Table 3** lists the responsibilities of clinicians when a child presents with symptoms suggestive of IBD.<sup>9,13</sup>

**Table 3. Interview and Physical Examination Procedures to Undertake When Pediatric Patients Present With IBD Symptoms<sup>9,13</sup>**

Interview
<ul style="list-style-type: none"><li>• Assess patient history</li><li>• Solicit patient's recent infections</li><li>• Determine patient's medicine use (especially antibiotics or NSAIDs)</li><li>• Determine travel history</li><li>• Determine family medical history (paying specific attention to an IBD diagnosis or related symptoms)</li><li>• Ascertain features of extraintestinal manifestations involving mouth, skin, eyes, and joints</li><li>• Question patient or parent on any episodes of perineal abscess or anal fissure</li></ul>
Physical Examination
<ul style="list-style-type: none"><li>• Assess general well-being</li><li>• Assess anthropometrics (weight, height, body mass index, growth percentiles)</li><li>• Assess temperature</li><li>• Inspect skin for rashes (eg, erythema nodosum)</li><li>• Inspect mouth</li><li>• Assess abdominal tenderness or distension</li><li>• Inspect for palpable masses</li><li>• Inspect for perineal disease</li><li>• Assess joints for arthritis</li></ul>

Children with IBD often display symptoms of chronic illness that may help clinicians suspect IBD early in the course of evaluation.<sup>9</sup> These symptoms include variable abdominal pain, chronic diarrhea (either with or without blood in the stool), perianal lesions, growth failure, and weight loss. Growth failure is present at diagnosis in 10% to 40% of children with IBD.<sup>19</sup> Weight loss is present in 85% of pediatric CD patients and 65% of pediatric UC patients.<sup>13</sup> Children with new onset IBD compared to adults are more likely to present with pancolitis; therefore, systemic symptoms such as anemia and fatigue may be more common.<sup>19</sup>

Like many pediatric patients presenting with IBD symptoms, Michelle was tested for various pathogens. Tests typically include *Salmonella*, *Shigella*, *Yersinia*, *Campylobacter*, *Escherichia coli*, and *Clostridium difficile*.<sup>5</sup> When these tests came back negative, Michelle underwent a colonoscopy and upper endoscopy.

## Differentiating UC From ASLC

The primary findings used to differentiate IBD from infection are duration of diarrhea and stool cultures.<sup>5</sup> Patients with no identified pathogen and/or symptom duration of more than 2 weeks are likely to have IBD. However, the sensitivity of stool cultures is imperfect, ranging from 40% to 80%. Furthermore, *Campylobacter* and *Clostridium difficile* can trigger the first flare of UC; thus, it is possible for infection and IBD to coexist.

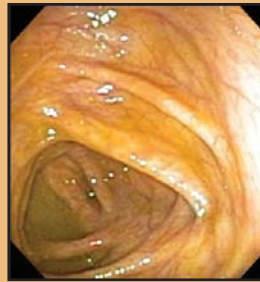Therefore, the critical test in establishing the diagnosis of IBD is a carefully performed upper endoscopy and colonoscopy with accurate description of the endoscopic findings (see **Figures 1A-1D**).<sup>5</sup> Simultaneously, tissue biopsy samples should be taken from each region of the lower bowel (terminal ileum, cecum, ascending colon, transverse colon, descending colon, sigmoid, and rectum). Each regional biopsy sample should be placed in a different formalin container and sent to the pathologist with an accurate description of the endoscopic findings, and the precise region where the biopsy was taken. Proper performance of the biopsies will enable the pathologist to provide a more accurate diagnosis.

## Colonoscopy With Biopsy Can Help Distinguish ASLC From IBD

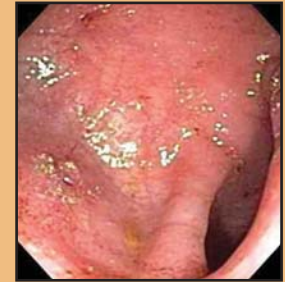Because stool cultures are not foolproof, more clinicians rely on early colonoscopy with biopsy to conclusively differentiate pediatric IBD from ASLC.<sup>5</sup> ASLC is a condition most often caused by infectious pathogens with features that overlap idiopathic IBD, but without many of the histologic criteria seen in IBD.

Several studies in adults have demonstrated that colonoscopy with biopsy in patients with acute colitis and negative cultures within 5 to 7 days of symptom onset can distinguish ASLC from IBD.<sup>5,26-28</sup>

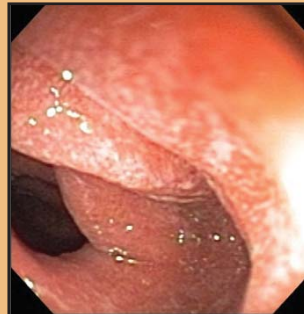In 1995, Mantzaris and colleagues examined the effectiveness of colonoscopy when performed at the onset of acute, severe hemorrhagic colitis.<sup>26</sup> The study involved 114 adult patients and compared the colonoscopic diagnosis with the final diagnosis of colitis (based on clinical, microbiological, endoscopic, and histologic criteria during the acute illness, and on the results of a 30-month follow-up of the patients). Colonoscopy diagnosed UC in 40 patients, CD in 4 patients, and infective colitis in 70 patients. The endoscopic diagnosis was confirmed by long-term follow-up in all 33 UC patients and 97% of the infective colitis patients, leading the authors to conclude colonoscopy was useful in differentiating severe bloody diarrhea of unknown etiology. The endoscopic features that were helpful in differentiating IBD from ASLC included diffuse erythema (seen in 100% of UC patients vs 25% of ASLC patients), granularity (100% vs 8%, respectively), and friability (100% vs 12%, respectively). In contrast, patchy erythema and microaphthoid ulcerations were more commonly seen in ASLC. However, endoscopic appearance alone may be misleading, and histologic evaluation is essential.



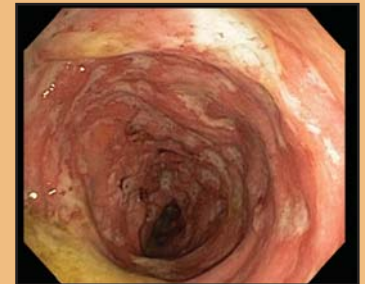**Figure 1A. Normal Colon: Endoscopic View.** Note orange-pink mucosa, well-seen blood vessels (normal vascular pattern). There is no ulceration or bleeding.



**Figure 1B. ASLC Versus UC.** There are regions of patchy granularity and loss of vascular pattern, but other regions where the vascular pattern is normal and easily visible. With this appearance, clinicians cannot reliably distinguish between ASLC and early UC, and multiple biopsies of both affected and less affected regions are essential.



**Figure 1C. UC: Endoscopic View.** There is diffuse inflammation involving the entire circumference of the bowel, with no visible normal areas. Examination of the mucosa reveals a loss of the vascular pattern, granularity (sandpaper appearance to the colon), and erythema. Other features not seen on this biopsy are friability (hemorrhage when the endoscope rubs the colonic mucosa), and mucopurulent exudate (mucopus).

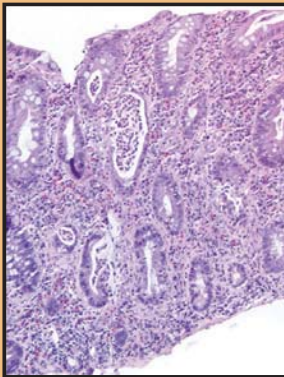


**Figure 1D. Crohn's Colitis: Endoscopic View.** There is evidence of cobblestoning and deep ulcerations. The ulceration is patchy and circumferential. Uninvolved areas have a normal vascular pattern and no granularity.

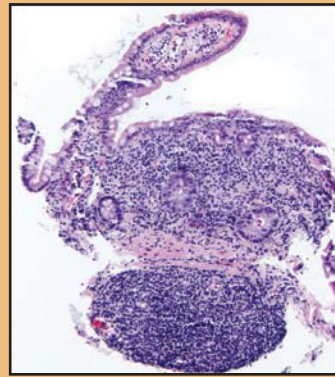
(Photos courtesy of Athos Bousvaros, MD, MPH)

## Histologic Features Are Crucial in Distinguishing ASLC From IBD

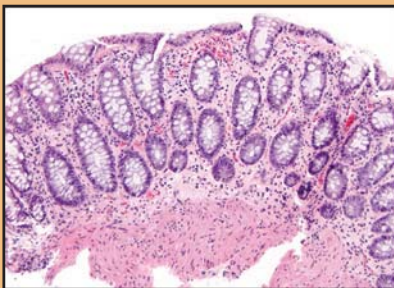
Histology also plays a critical role in separating ASLC from IBD. The North American Society for Pediatric Gastroenterology, Hepatology, and Nutrition (NASPGHAN) Working Group stated that histologic features present in UC but rarely in ASLC include basal lymphoplasmacytosis, crypt architectural distortion (including irregular crypt shape or placement, branching, atrophy, or surface villiform change), and crypt Paneth cell metaplasia in left colonic biopsies.<sup>5</sup> The role of pathologists in differentiating ASLC from IBD (especially CD) based on biopsy results is crucial because these histologic features are often subtle.



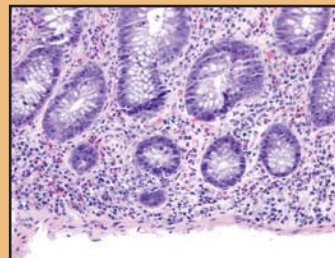
**Figure 2A. ASLC Histology.** Original magnification 100x, hematoxylin and eosin. The crypt architecture remains normal with even spacing of crypts that extends to the muscularis mucosae. However, the epithelium is infiltrated with neutrophils that form luminal aggregates termed crypt abscesses.



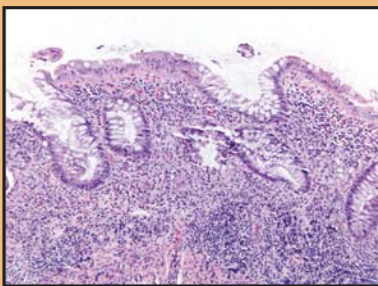
**Figure 2B. Normal Terminal Ileal Mucosa Histology.** Original magnification 100x, hematoxylin and eosin. The villi are tall and slender. The lamina propria and submucosa contains a lymphoid aggregate, which is a normal constituent of the terminal ileum.



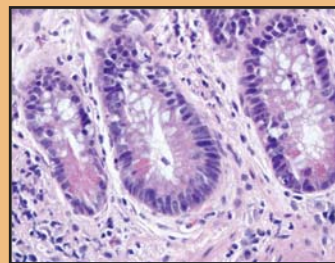
**Figure 2C. Normal Colonic Mucosa Histology.** Original magnification 100x, hematoxylin and eosin. The crypt architecture is normal with evenly spaced crypts that fully extend to the muscularis mucosae. The lamina propria inflammation is of highest density toward the luminal aspect.



**Figure 2D. Chronic Mildly Active Colitis Histology.** Original magnification 200x, hematoxylin and eosin. The most sensitive histologic feature of chronicity is the presence of a lymphoplasmacytic infiltrate between the base of the crypts and the muscularis mucosae, termed “basal plasmacytosis.” Note the presence of a mild neutrophilic infiltrate within the epithelium.



**Figure 2E. Chronic Active Colitis Histology.** Original magnification 100x, hematoxylin and eosin. As the chronic changes become more severe, the crypts become foreshortened and the space between the base of the crypts and the muscularis mucosae increases. Note the abnormal spacing and configuration of crypts, termed “crypt distortion.” Again, a mild neutrophilic infiltrate is seen.



**Figure 2F. Chronic Inactive Colitis.** Original magnification 200x, hematoxylin and eosin. Another feature of chronic colitis is Paneth cell metaplasia, seen here. Paneth cells are abnormal distal to the midtransverse colon and can be regarded as a feature of chronicity.

(Photos courtesy of Jeffrey Goldsmith, MD)

The subtle histologic features (see Figures 2A-2F) are a primary reason the NASPGHAN Working Group recommends obtaining biopsies from several locations since multiple biopsies give pathologists a better opportunity to make accurate distinctions.

In the Mantzaris study, histologic features consistent with chronic UC but not ASLC included basal plasmacytosis, basal lymphoid aggregates, and crypt branching.<sup>26</sup> Other studies have found similar histologic criteria to differentiate between ASLC and UC. In a study of 168 patients with bloody diarrhea, Nostrant and colleagues noted that crypt distortion and basal plasmacytosis did not appear in cases of ASLC.<sup>29</sup> Similarly, Surawicz and colleagues showed that branched glands appeared in only 5 of 52 patients with ASLC, and just 1 patient with ASLC had evidence of basal lymphoid aggregates.<sup>27</sup>

In summary, in patients with acute onset bloody diarrhea and negative stool cultures, colonoscopy with biopsy can help distinguish between ASLC and new onset IBD. Endoscopic features that suggest IBD include endoscopic granularity, friability, and erythema.<sup>26</sup> Histologic findings that suggest IBD include crypt branching, crypt distortion, and basal lymphoplasmacytosis.<sup>26,27</sup>

### Clinicians Must Determine Cause of Focal Active Colitis in Pediatric Patients

In some patients, focal active colitis (FAC) may be seen in endoscopic biopsies.<sup>30</sup> FAC is defined as “the isolated finding of focal infiltration of the colonic epithelium by neutrophils.” FAC may be

seen in early onset CD and UC, but may also be seen in ASLC and as an adverse event associated with bowel preparation.<sup>31</sup> Clinicians must differentiate FAC caused by actual disease from that caused by bowel preparations. For example, agents used to cleanse the colon before endoscopy (ie, sodium phosphate, magnesium citrate) can produce aphthous ulcers.

Typically, features of FAC caused by actual disease include minimal apoptosis and cryptitis surrounded by lymphocytes and macrophages (possibly with mucin granulomas) in the lamina propria.<sup>5</sup> If a child with chronic or bloody diarrhea has findings of FAC on biopsy, but no other features specific for IBD, the NASPGHAN Working Group recommends that he/she be followed clinically, since he/she may go on to develop IBD.

### Case 1 Summary: Michelle



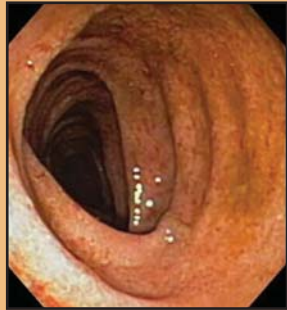Michelle’s gastroenterologist performed a colonoscopy and ileoscopy (see Figure 3A). The macroscopic features included granularity and friability of the entire colon, with mild ileal nodularity consistent with Peyer’s patches. The left side of the colon was more severely involved. During the procedure, the gastroenterologist performed biopsies of each region of the visualized intestine (ileum, ascending colon, transverse

colon, descending colon, sigmoid colon, and rectum). Biopsies from each region were placed in a separate vial and sent to the pathologist.

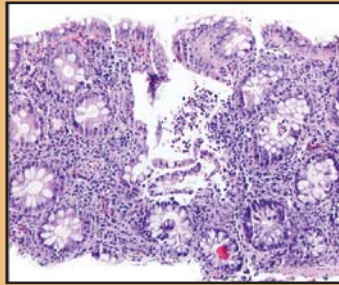
Ileal biopsies were normal, and biopsies from the ascending and transverse colon showed active colitis only (see **Figure 3B**).

However, biopsies from the other regions of the colon demonstrated chronic active colitis, with basal lymphoid aggregates and crypt branching (see **Figure 3C**).

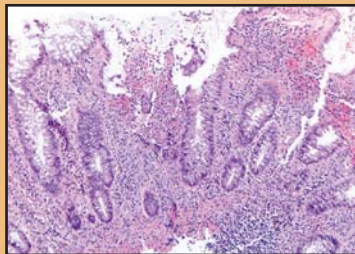
Because of the evidence of chronic change on pathology, the patient was given a diagnosis of UC rather than infectious colitis. She was started on oral prednisone and improved within 72 hours.



**Figure 3A. Michelle's Colon: Endoscopic View Demonstrating Diffuse Continuous Colitis.**



**Figure 3B. Moderately Active Colitis.** Original magnification 100x, hematoxylin and eosin. The crypt architecture is intact in this biopsy. However, multiple crypt abscesses are seen.



**Figure 3C. Chronic Severely Active Colitis.** Original magnification 100x, hematoxylin and eosin. This biopsy shows chronic changes as illustrated by the basal plasmacytosis and crypt dropout. Additionally, there is surface erosion present in the center of the photograph.

(Photos courtesy of Athos Bousvaros, MD, MPH and Jeffrey Goldsmith, MD)

## Case 2 Presentation: Differentiating UC From CD of the Colon



Peter is an 8-year-old male patient with a 4-week history of bloody diarrhea who is referred to you for evaluation. His stool cultures are negative. A colonoscopy has revealed that the entire colon is inflamed, but the rectum is less inflamed. The patient's ileocecal valve is easily intubated and the terminal ileum appears normal. The written pathology report cites that there are features of chronic active colitis

(crypt branching, crypt abscesses) seen throughout the colon. However, the pathologist also reports that microscopic inflammation was present in the ileum. An upper gastrointestinal series with small bowel follow-through (SBFT) appears within normal limits. You are wondering whether the patient has CD or UC.

## Distinguishing Between Pediatric CD and UC

The epidemiologic diagnosis of UC depends on whether the following features are present<sup>3,5,19</sup>:

- Bloody diarrhea with negative stool cultures
- Endoscopic evidence of diffuse continuous mucosal inflammation involving the rectum and extending to a point more proximal in the colon
- In most children, UC extends proximally to the splenic flexure or involves the entire colon (extensive colitis)

In contrast to UC, CD has a number of heterogeneous subtypes, some of which involve the small bowel, some of which involve the colon, and some of which involve both areas.<sup>5</sup> The definition of CD is unambiguous if there is clear radiographic and/or endoscopic evidence of small bowel and proximal colon involvement, but the distal colon is normal. In addition, other features that enable a definitive diagnosis of CD include multiple noncaseating granulomas on endoscopic mucosal biopsy or evidence of severe perianal disease (fissures or fistulae). However, when CD is limited to the colon and granulomas are not present on biopsies, the diagnosis is more problematic. At that point, an endoscopist must differentiate CD from UC based on the endoscopic appearance at the time of initial colonoscopy. Endoscopic features consistent with Crohn's colitis include focal discontinuous inflammation (skip areas), deep fissuring ulcers (cobblestoning), and aphthous lesions superimposed on a background of normal colonic mucosa.<sup>5,32</sup>

The NASPGHAN Working Group recommends that clinicians who initially evaluate children with IBD search for characteristics suggestive of CD.<sup>5</sup> These characteristics include granulomas not adjacent to crypts, macroscopic small bowel involvement (seen either on radiography or ileoscopy), colonic stricturing, cobblestoning, or pronounced perianal disease. In patients with IBD limited to the colon and histologic features of chronicity, if the above features are not present, and there is diffuse continuous colitis, the diagnosis is most likely UC.

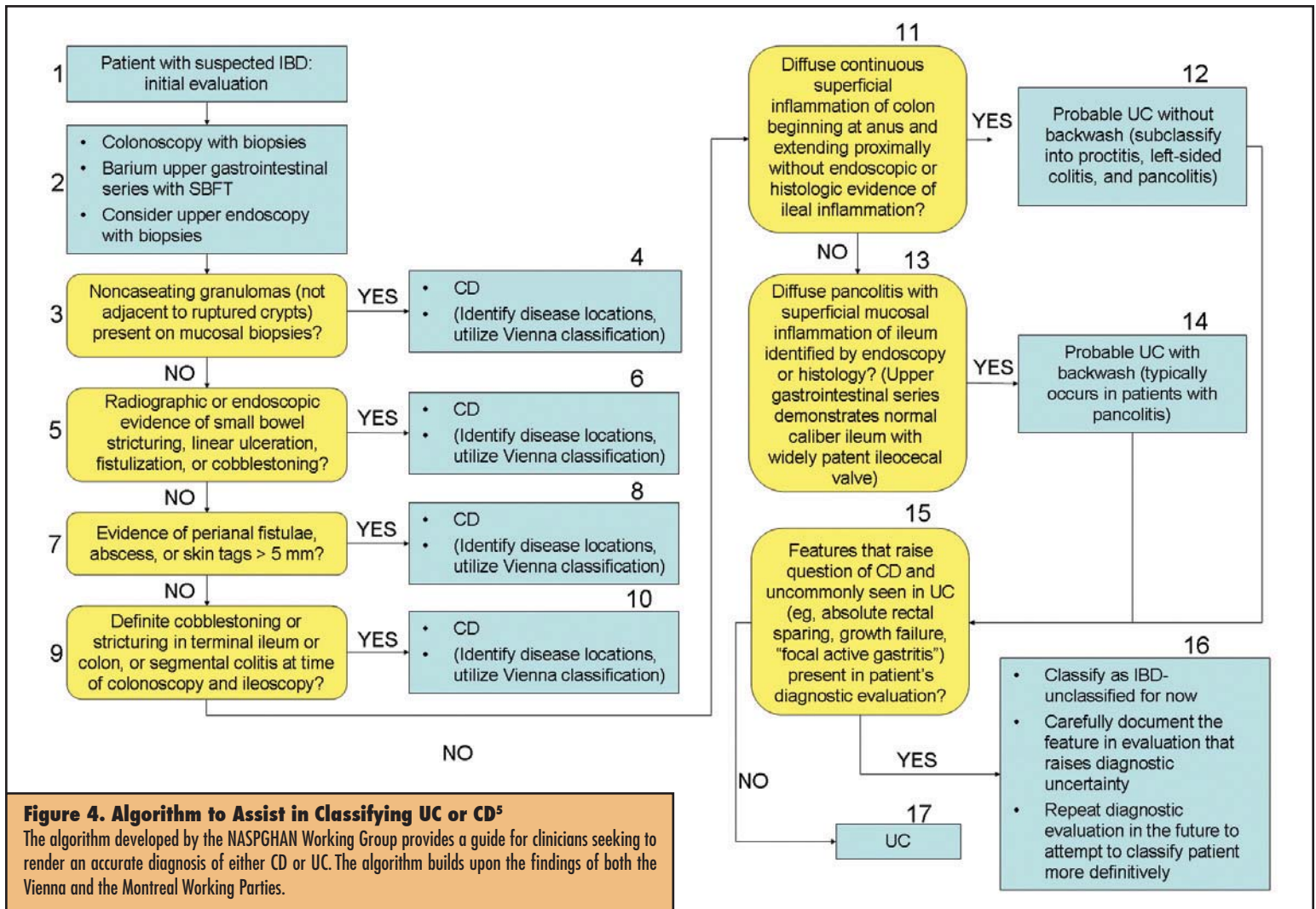
**Table 4** lists histologic features that differentiate UC from CD.<sup>5</sup>

**Table 4. Histologic Features Helpful in Distinguishing Between UC and CD<sup>5</sup>**

	Typical/Definite	Less Common but Compatible (or Needs Further Study)	Incompatible
UC	<ul style="list-style-type: none"> <li>• Chronic or chronic active colitis (crypt architectural distortion, basal lymphoplasmacytosis, distal Paneth cell metaplasia)</li> <li>• Inflammation limited to mucosa</li> <li>• Continuous involvement, including rectum</li> <li>• No extracolonic involvement</li> </ul>	<ul style="list-style-type: none"> <li>• Deeper or transmural inflammation (in fulminant colitis)</li> <li>• Discontinuous inflammation in cecum or appendix (cecal patch)</li> <li>• Absent or subtle features if chronic colitis early in disease course</li> <li>• Backwash ileitis</li> <li>• Duodenitis or gastritis not typical of CD</li> </ul>	<ul style="list-style-type: none"> <li>• True (nonpericrypt) granulomas</li> <li>• Ileal or small intestinal involvement not consistent with backwash ileitis</li> <li>• Transmural lymphoid aggregates</li> <li>• Perianal granulomatous inflammation within skin tags</li> </ul>
CD	<ul style="list-style-type: none"> <li>• Chronic or chronic active ileitis or colitis (colonic findings similar to UC but commonly patchy; ileal findings include active ileitis, crypt distortion, pyloric metaplasia)</li> <li>• Granulomas (nonpericrypt)</li> <li>• Discontinuous inflammation with intervening zones of normal bowel</li> <li>• Fissuring ulceration, stricture and fistula formation</li> </ul>	<ul style="list-style-type: none"> <li>• Inflammation limited to mucosa</li> </ul>	<ul style="list-style-type: none"> <li>• None</li> </ul>

Differentiating between CD and UC requires the integration of endoscopic findings and histologic interpretation.<sup>5</sup> Clinicians who rely solely on endoscopic findings to render diagnoses may not identify granulomatous inflammation that would change the diagnosis from UC to CD. On the other hand, clinicians who only rely on histologic findings may incorrectly classify patients with UC as having CD on the basis of nonspecific mucosal inflammatory alterations.

The algorithm developed by the NASPGHAN Working Group (shown in **Figure 4**) provides a guide for clinicians seeking to render an accurate diagnosis of either CD or UC.<sup>5</sup> The algorithm builds upon the findings of both the Vienna and the Montreal Working Parties.



### Nonclassical Features That May Be Seen in Pediatric UC

Recent advances in diagnostic testing, (eg, video capsule endoscopy, abdominal magnetic resonance imaging [MRI] scans, serologies) combined with the routine performance of upper endoscopy, colonoscopy, and terminal ileoscopy, have given clinicians more tools to obtain clinical information on pediatric IBD patients. However, the abundance of clinical data has also made properly classifying IBD patients more difficult. Some atypical features that may be seen in UC that may cause uncertainty about the diagnosis are listed in **Table 5**.<sup>5</sup> In this monograph, we will review 5 atypical features and discuss their prevalence in patients with UC: backwash or microscopic ileitis, gastritis, cecal patch (periappendiceal inflammation), patchy histology, and relative rectal sparing.

**Table 5. Nonclassical Findings at Presentation in Patients With UC That Do Not Exclude Diagnosis of UC<sup>5</sup>**

Clinical
<ul style="list-style-type: none"> <li>Small anal fissures or skin tags (&lt; 5 mm)</li> <li>Oral ulcers</li> <li>Growth impairment</li> </ul>
Endoscopic
<ul style="list-style-type: none"> <li>Gastritis without aphthae</li> <li>Backwash ileitis – ileal erythema without linear ulceration</li> <li>Periappendiceal inflammation in patients without pancolitis</li> <li>Rectal inflammation less severe than in more proximal colon (relative rectal sparing)</li> </ul>
Histologic
<ul style="list-style-type: none"> <li>Microscopic ileitis without granuloma</li> <li>Microscopic gastritis without granuloma</li> <li>Relative rectal sparing (histological inflammation less severe in rectum)</li> <li>Patchiness (normal colonic mucosa between 2 areas of colonic inflammation)</li> </ul>

### Characteristics: Backwash Ileitis in UC

Although the term has often been misused and misunderstood, “backwash ileitis” (or ileal inflammation seen in UC) describes an abnormal appearance of the terminal ileum in patients with ulcerative pancolitis.<sup>5</sup> In contrast, backwash ileitis is generally not seen in patients with left-sided colitis. Radiographic studies of patients with backwash ileitis have shown that a rough “sandpaper” appearance may be present in the terminal ileum.<sup>33</sup> However, the terminal ileum is not stenotic, and the ileocecal valve is widely patent. Colonoscopy in patients with backwash ileitis demonstrates pancolitis, a normal ileocecal valve, and a granular ileum without stricture, stenosis, or ulceration.<sup>5</sup> Ileal erythema and granularity are diffuse and typically extend < 10 cm proximal to the ileocecal valve. Normal lymphoid nodules may be present, but there is no evidence of linear ulcerations, deep fissures, or cobblestoning.

### Backwash Ileitis Versus Crohn's Ileocolitis

One challenge for the clinician who treats Peter is determining whether Peter has UC with backwash ileitis or Crohn's ileocolitis. The specific histologic features separating the 2 disorders have not been defined, and differentiating these 2 entities may rest primarily on the endoscopic appearance.

The NASPGHAN Working Group identified ulceration and stenosis of the ileocecal valve, cobblestoning or linear ulcerations in the ileum, and granulomatous inflammation on ileal or biopsy as features seen in Crohn's ileocolitis and not backwash ileitis.<sup>5</sup> In order to standardize the descriptions of ileitis, the NASPGHAN Working Group also suggested the following<sup>5</sup>:

- Normal ileum:** an ileum that is both macroscopically and microscopically normal, without features of inflammation; lymphoid nodularity of terminal ileal Peyer's patches should be considered a normal finding
- Histologic backwash ileitis:** active ileitis (focal or diffuse) with or without features of chronicity identified on histologic examination, with an endoscopically normal ileum.

- **Endoscopic and histologic backwash ileitis:** endoscopic erythema and granularity or terminal ileum, confirmed upon histology with findings of active or chronic ileitis
- **Crohn's ileocolitis:** linear ulceration, cobblestoning, and narrowing of ileum, often associated with ulceration of ileocecal valve; findings may be demonstrated either by endoscopy of terminal ileum or by barium upper gastrointestinal with SBFT contrast study; the histology may be normal (due to focal nature of inflammation) or demonstrate acute and chronic ileitis; presence of noncaseating granulomas on ileal biopsy automatically classifies a patient as having Crohn's ileocolitis (assuming exclusion of infectious causes of ileitis).

### Gastritis and Upper Endoscopic Findings in Children With UC and CD

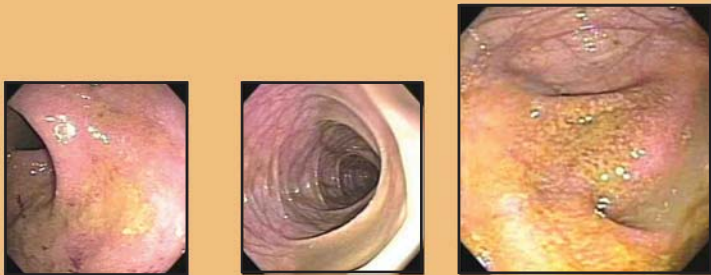
Upper gastrointestinal inflammation has been observed in approximately 30% of patients with CD.<sup>5</sup> This inflammation may cause delayed gastric emptying.<sup>34</sup> However, children with UC may also have gastritis.<sup>5</sup> Multiple trials have revealed that the prevalence of inflammation seen in the esophagus, stomach, and duodenum is similar in UC and CD. Upper endoscopic findings shared by UC and CD include esophagitis, esophageal ulcer, nonspecific gastritis, duodenitis, and duodenal ulcers.<sup>35-37</sup> However, routine biopsies of the esophagus, stomach, and duodenum are indicated because they may identify noncaseating granulomas in a significant minority of patients. If granulomas are identified on the upper gastrointestinal endoscopy, and other causes of granulomatous inflammation (ie, *Helicobacter pylori*) are eliminated, the patient should be diagnosed with CD.<sup>5</sup>

### Periappendiceal Inflammation (Cecal Patch)

In some patients with UC that does not involve the entire colon, there may be signs of macroscopic and histologic periappendiceal inflammation. Endoscopists evaluating such a patient will typically see signs of rectal, sigmoid, and left-colon inflammation. The transverse and ascending colon, and the terminal ileum will appear normal. However, the cecum may demonstrate some mild granularity and erythema around the appendix. Biopsies may demonstrate a mild active colitis in the cecum. This variant, called the cecal patch (**Figure 5**), is well described in UC and should not be confused for a "skip area" that would suggest CD.<sup>38,39</sup>

#### Figure 5. Periappendiceal Inflammation or "Cecal Patch."

This finding is noted in patients with left-sided UC or ulcerative proctitis. On colonoscopy, there is evidence of distal inflammation from the anus up to some point in the descending colon. More proximally, the colonic mucosa is normal in the transverse and ascending colon. Upon visualization of the cecum, there is evidence of localized periappendiceal granularity. Biopsy of the "cecal patch" may demonstrate histologic evidence of colitis.



(Photos courtesy of Athos Bousvaros, MD, MPH)

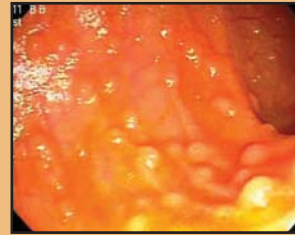
### Patchiness and Rectal Sparing in UC

Classical UC is a diffuse continuous disease that begins in the rectum and extends proximally.<sup>5</sup> Thus, the severity of inflammation should be similar in all biopsies of the inflamed region of the colon. However, in some children, a patchy colitis may be present.

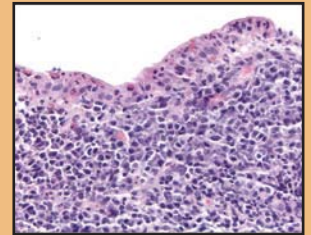
The term "patchiness" has been defined as areas of normal mucosa (either endoscopically or histologically) between 2 areas of colonic inflammation.<sup>5</sup> In a study by Glickman and colleagues, patchy histology was present in 21% of the children with newly diagnosed UC.<sup>40</sup> Similarly, "relative rectal sparing" (inflammation less severe in the rectum than in the more proximal colon) was present in 27% of the children.<sup>5,40</sup>

Washington and colleagues demonstrated that initial rectal biopsies from children with UC are less likely to show diagnostic mucosal architectural distortion compared to adult biopsies.<sup>41</sup> The authors speculated that the difference was due to the shorter duration of symptoms in children (mean: 17.5 weeks) than adults (mean: 54.9 weeks) before biopsy. However, absolute rectal sparing (normal rectum both on endoscopy and a normal rectal histology) is unusual in pediatric UC.<sup>5,40</sup>

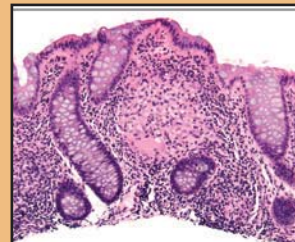
In summary, patients with UC may have any of the nonclassical features described above. When patients have diffuse continuous colitis and show these nonclassical features - with no other features suggestive of CD - clinicians can diagnose UC.<sup>5</sup>



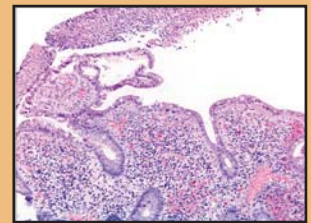
**Figure 6A. Normal Ileum: Endoscopic View.** While Peyer's patches are present, there is no stenosis, ulceration, or cobblestoning.



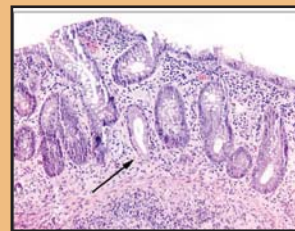
**Figure 6B. Mildly Active Ileitis.** Original magnification 200x, hematoxylin and eosin. This is a moderate power photomicrograph of the surface of the terminal ileum. The surface epithelium is infiltrated by neutrophils. Neither ulcerations, granulomas, nor chronic changes were seen in this biopsy. These findings are consistent with "backwash ileitis."



**Figure 6C. Noncaseating Granuloma in Colon.** Original magnification 100x, hematoxylin and eosin. A well-defined cluster of epithelioid histiocytes is present in the lamina propria. Note that Peter's granuloma is unassociated with crypt inflammation.



**Figure 6D. Chronic Severely Active Ileitis.** Original magnification 100x, hematoxylin and eosin. The significant villous atrophy is sufficient for the diagnosis of chronic ileitis. Also, there is significant neutrophilic inflammation in the epithelium with a fragment of fibrinopurulent exudate in the upper left of the photograph. The fibrinopurulent exudate is consistent with ulceration.



**Figure 6E. Chronic Mildly Active Ileitis.** Original magnification 100x, hematoxylin and eosin. This ileal biopsy shows chronic changes, as evidenced by the marked villous atrophy and the presence of pyloric gland metaplasia (arrow). Rare neutrophils are present in the epithelium.

(Photos courtesy of Athos Bousvaros, MD, MPH and Jeffrey Goldsmith, MD)

## Case 2 Summary: Peter



Because of the question of ileal inflammation seen on biopsy, you review both your colonoscopy report and the upper gastrointestinal/SBFT series. The ileum and ileocecal valve were macroscopically normal, with no gross ulceration, inflammation, or narrowing (**Figure 6A**).

Upon direct second review of the histology with the pathologist, the microscopic ileitis noted was confined to the presence of a few neutrophils overlying a Peyer's patch (**Figure 6B**).

No ulceration or granulomas were seen to suggest Crohn's ileocolitis (**Figures 6C-6E**). You therefore decide to classify this patient as having UC instead of Crohn's colitis.

## Case 3 Presentation: Approach to a Patient With IBD-Unclassified ("Indeterminate Colitis")



Kyle, a 16-year-old male, is referred to you for a second opinion regarding his diagnosis. Kyle has refractory colitis that has not responded to medical treatment with prednisone and 6-mercaptopurine.

When you review his initial evaluation, you note that he had a left-sided colitis. He has a normal ascending and transverse colon. However, he also had a few tiny ulcers in the terminal ileum. No granulomas were seen.

You obtain an IBD serologic panel, which demonstrates a positive perinuclear antineutrophil cytoplasmic antibody and a negative anti-*Saccharomyces cerevisiae* antibody. You are unsure of his diagnosis.

### "Indeterminate Colitis" Is Now Called "IBD-Unclassified"

The lack of consensus criteria for IBD disease types is most evident in cases of IBD-unclassified, also known as indeterminate colitis.<sup>3,23,42,45</sup> The term "indeterminate colitis" has been used for more than 25 years to describe a group of patients with IBD limited to the colon who have features that make distinguishing between CD and UC difficult.<sup>5</sup> Originally, the term "indeterminate colitis" was proposed by pathologists for colectomy specimens, usually from patients with severe colitis, showing overlapping features of UC and CD. Later, the meaning of indeterminate colitis evolved to describe patients displaying no clear clinical, endoscopic, histologic, and other features to justify a diagnosis of either UC or CD.<sup>45</sup> Currently, the preferred term is "IBD-unclassified."

Epidemiologic studies of children have reported that the prevalence of IBD-unclassified ranges from 4% to 30%.<sup>21,46,47</sup> The wide range in prevalence suggests that previous studies are likely describing different patient populations with IBD-unclassified, mainly due to interobserver variation and a lack of exact criteria for diagnosing the disease.<sup>5,48</sup> Because its definition is imprecise, a diagnosis of IBD-unclassified may reflect a clinician's diagnostic uncertainty rather than clinical data. In addition to the uncertainty many clinicians face regarding the diagnosis of IBD-unclassified, there may be considerable variation in how pathologists interpret colonic biopsies.<sup>24</sup>

### Implications of Pediatric IBD-Unclassified Patients

The Montreal Working Group has recently proposed for the replacement of the term "indeterminate colitis" with the more accurate term "IBD-unclassified."<sup>18</sup> The clinical course of IBD-unclassified has not been well defined in children.<sup>21</sup> It remains unknown whether IBD-unclassified patients have different long-term outcomes compared to UC patients, whether they face increased risks of pouchitis after surgery, or how many of them develop features of CD.<sup>5</sup>

Some patients with IBD-unclassified evolve to a definite diagnosis of UC or CD on follow-up.<sup>48</sup> A prospective longitudinal study conducted by Joossens and colleagues in 2002 tracked 97 patients with IBD-unclassified.<sup>23</sup> A total of 32% of the patients with an initial diagnosis of IBD-unclassified and positive serology testing were ultimately reclassified as having either UC or CD (mean disease duration: 6 years). Therefore, longitudinal follow-up and repeat endoscopic and histologic

evaluation of the patient with IBD-unclassified is prudent before making major therapeutic decisions (eg, prescribing infliximab, recommending surgery).

In patients with IBD-unclassified, a number of diagnostic modalities exist to help clinicians further characterize the disease. Of these, perhaps the best studied are serologies. A commercially-available panel of 7 antibodies has a high sensitivity for IBD.<sup>49</sup> Of these antibodies, the anti-*Saccharomyces cerevisiae* is thought to be highly specific for CD. If this antibody is positive in a patient with IBD-unclassified, clinicians should suspect CD. Other modalities that may have utility include video capsule endoscopy and abdominal MRI.<sup>33,50</sup> However, it is unclear how useful these tests are in allowing the clinician to reclassify the patient with IBD-unclassified.

Even if the definition of IBD-unclassified was standardized, patients diagnosed with IBD-unclassified may actually be a heterogeneous subset of IBD.<sup>51</sup> Some may have colitis that cannot be subclassified into UC or CD despite thorough investigations by an IBD specialist. Others designated as IBD-unclassified may have UC or CD if investigated by a more knowledgeable clinician. While IBD-unclassified should be considered an interim diagnosis in children with IBD, some patients may remain "indeterminate" despite serial diagnostic procedures and the availability of serologic testing.<sup>21</sup>

### Toward a More Precise Definition of IBD-Unclassified

In order to better understand IBD-unclassified, the NASPGHAN Working Group suggests that the following features may be used to characterize a patient as IBD-unclassified<sup>5</sup>:

- Colitis with an endoscopically and histologically normal rectum (absolute rectal sparing)
- Mild ileitis with features atypical for backwash (eg, ileal aphthae)
- Microscopic ileitis seen in patients with colitis limited to the left colon
- Severe focal gastritis
- Pancolitis with anal fissures or tags
- Colitis with growth failure

The NASPGHAN Working Group also suggests that clinicians clearly document in the medical record the precise clinical data that prompted them to diagnose IBD-unclassified.<sup>5</sup> In follow-up studies, if these features resolve, clinicians may elect to change the patient's diagnosis from IBD-unclassified to either CD or UC.

## Case 3 Summary: Kyle



As in Case 2, the gastroenterologist carefully reviewed the endoscopic and histologic features with his pathologist a second time. The endoscopic report demonstrated granularity, friability, and loss of vascular pattern extending from the mid-descending colon to the rectum. The histology was consistent with chronic colitis, but no granulomas were seen. The right colon and transverse colon appeared normal.

Though the ileum was widely patent, small ileal aphthae were visible; ileal biopsy confirmed the ulceration, but no granulomas were seen. The left-sided colonic disease without granulomas suggested left-sided UC, but the tiny ileal ulcers raised the question of CD.

Based on the ileal findings in a patient with left-sided colitis, the patient was given a diagnosis of "IBD-unclassified." The patient was started on infliximab therapy, and a plan was made for a follow-up colonoscopy in 6 months to try to establish a more definitive diagnosis of CD or UC.

## Summary

The challenges of correctly classifying and diagnosing pediatric IBD diseases are apparent, as is the clinical importance of doing so. An accurate diagnosis enables clinicians to clearly discuss diagnosis and treatment options with patients and their families. Beyond its implications for therapy, a clearly defined diagnosis is crucial to the conduct of epidemiologic studies and clinical trials. Widely agreed-upon consensus terminology enables clinicians to "talk the same language." We hope this monograph clarifies some of the confusing aspects of pediatric IBD diagnosis and will be useful in evaluating children with suspected IBD.

**Thank you for participating in this activity.**

To take the posttest and evaluation and receive credit, please go to: [http://www.gotomylist.com/evaluator/evaluation\\_start.cfm?pk\\_event=271](http://www.gotomylist.com/evaluator/evaluation_start.cfm?pk_event=271) or review page 2 under "How to Receive CME Credit" for further details.

# Improve Your IBD Patient Outcomes



This activity is part of an ongoing educational series on pediatric IBD.

Topics include: - Diagnosis - Transitioning Care  
- Monitoring disease activity - More to come...  
- Treatment Safety



Click here to visit [www.pedibd.org](http://www.pedibd.org)

## References

1. Inflammatory bowel disease in children and adolescents. Children's Digestive Health and Nutrition Foundation Web site. <http://www.kidsibd.org/asp/public/ContentPage.aspx?pName=PatientsOverview&pType=en&nu=patients>. Accessed February 19, 2009.
2. About Crohn's disease. Crohn's and Colitis Foundation of America Web site. <http://www.cffa.org/info/about/crohns>. Accessed February 19, 2009.
3. Kugathasan S, Judd RH, Hoffmann RG, et al. Epidemiologic and clinical characteristics of children with newly diagnosed inflammatory bowel disease in Wisconsin: a statewide population-based study. *J Pediatr*. 2003;143:525-531.
4. Bousvaros A, Sylvester F, Kugathasan S, et al. Challenges in pediatric inflammatory bowel disease. *Inflamm Bowel Dis*. 2006;12:885-913.
5. Bousvaros A, Antonioli DA, Colletti RB, et al. Differentiating ulcerative colitis from Crohn disease in children and young adults: report of a working group of the North American Society for Pediatric Gastroenterology, Hepatology, and Nutrition and the Crohn's and Colitis Foundation of America. *J Pediatr Gastroenterol Nutr*. 2007;44:653-674.
6. Targan SR, Karp LC. Inflammatory bowel disease diagnosis, evaluation and classification: state-of-the-art approach. *Curr Opin Gastroenterol*. 2007;23:390-394.
7. Satsangi J, Silverberg S, Vermeire S, et al. The Montreal classification of inflammatory bowel disease: controversies, consensus, and implications. *Gut*. 2006;55:749-753.
8. Dubinsky M. Special issues in pediatric inflammatory bowel disease. *World J Gastroenterol*. 2008;14:413-420.
9. Hugot J-P, Belaiche M. Inflammatory bowel diseases: the paediatric gastroenterologist's perspective. *Pediatr Radiol*. 2007;37:1065-1070.
10. Kugathasan S, Baldassano RN, Bradfield JP, et al. Loci on 20q13 and 21q22 are associated with pediatric-onset inflammatory bowel disease. *Nat Genet*. 2008;40:1211-1215.
11. Krupoves A, Seidman EG, Mack D, et al. Associations between *ABC1/MDR1* gene polymorphisms and Crohn's disease: a gene-wide study in a pediatric population [published online ahead of print December 23, 2008]. *Inflamm Bowel Dis*. doi:10.1002/ibd.20849.
12. Strober W, Fuss I, Mannon P. The fundamental basis of inflammatory bowel disease. *J Clin Invest*. 2007;117:514-521.
13. Diefenbach KA, Breuer CK. Pediatric inflammatory bowel disease. *World J Gastroenterol*. 2006;12:3204-3212.
14. Garland CF, Lilienfeld AM, Mendeloff AI, et al. Incidence rates of ulcerative colitis and Crohn's disease in fifteen areas of the United States. *Gastroenterology*. 1981;81:1115-1124.
15. Olafsdottir EJ, Fluge G, Haug K. Chronic inflammatory bowel disease in children in western Norway. *J Pediatr Gastroenterol Nutr*. 1989;8:454-458.
16. Loftus EV Jr, Silverstein MD, Sandborn WJ, et al. Ulcerative colitis in Olmsted County, Minnesota, 1940-1993: incidence, prevalence, and survival. *Gut*. 2000;46:336-343.
17. Gasche C, Scholmerich J, Brynskov J, et al. A simple classification of Crohn's disease: report of the Working Party for the World Congresses of Gastroenterology, Vienna 1998. *Inflamm Bowel Dis*. 2000;6:8-15.
18. Silverberg MS, Satsangi J, Ahmad T, et al. Toward an integrated clinical, molecular and serological classification of inflammatory bowel disease: report of a Working Party of the 2005 Montreal World Congress of Gastroenterology. *Can J Gastroenterol*. 2005;19(suppl A):S-36.
19. IBD Working Group of the European Society for Paediatric Gastroenterology, Hepatology and Nutrition. Inflammatory bowel disease in children and adolescents: recommendations for diagnosis—the Porto criteria. *J Pediatr Gastroenterol Nutr*. 2005;41:1-7.
20. Medications. The Foundation for Clinical Research in Inflammatory Bowel Disease Web site. <http://www.myibd.org/PatientEducation/Medications>. Accessed February 19, 2009.
21. Carvalho RS, Abadam V, Dilworth HP, et al. Indeterminate colitis: a significant subgroup of pediatric IBD. *Inflamm Bowel Dis*. 2006;12:258-262.
22. Kaiser AM, Beart RW Jr. Surgical management of ulcerative colitis. *Swiss Med Wkly*. 2001;131:323-337.
23. Joossens S, Reinisch W, Vermeire S, et al. The value of serologic markers in indeterminate colitis: a prospective follow-up study. *Gastroenterology*. 2002;122:1242-1247.
24. Farmer M, Petras RE, Hunt LE, et al. The importance of diagnostic accuracy in colonic inflammatory bowel disease. *Am J Gastroenterol*. 2000;95:3184-3188.
25. Theodossi A, Spiegelhalter DJ, Jass J, et al. Observer variation and discriminatory value of biopsy features in inflammatory bowel disease. *Gut*. 1994;35:961-968.
26. Mantzaris GJ, Hatzis A, Archavlis E, et al. The role of colonoscopy in the differential diagnosis of acute, severe hemorrhagic colitis. *Endoscopy*. 1995;27:645-653.
27. Surawicz CM, Haggitt RC, Husseman M, et al. Mucosal biopsy diagnosis of colitis: acute self-limited colitis and idiopathic inflammatory bowel disease. *Gastroenterology*. 1994;107:755-763.
28. Konuma Y, Tanaka M, Saito H, et al. A study of the histological criteria for ulcerative colitis: retrospective evaluation of multiple colonic biopsies. *J Gastroenterol*. 1995;30:189-194.
29. Nostrant TT, Kumar NB, Appelman HD. Histopathology differentiates acute self-limited colitis from ulcerative colitis. *Gastroenterology*. 1987;92:318-328.
30. Xin W, Brown PI, Greenson JK. The clinical significance of focal active colitis in pediatric patients. *Am J Surg Pathol*. 2003;27:1134-1138.
31. Berkelhammer C, Ekambaram A, Silva RG. Low-volume oral colonoscopy bowel preparation: sodium phosphate and magnesium citrate. *Gastrointest Endosc*. 2002;56:89-94.
32. Yao T, Matsui T, Hiwatashi N. Crohn's disease in Japan: diagnostic criteria and epidemiology. *Dis Colon Rectum*. 2000;43(suppl):S85-S93.
33. Laghi A, Borrelli O, Paolantonio P, et al. Contrast enhanced magnetic resonance imaging of the terminal ileum in children with Crohn's disease. *Gut*. 2003;52:393-397.
34. Kristinsson JO, Hopman WP, Oyen WJ, et al. Gastroparesis in patients with inactive Crohn's disease: a case series. *BMC Gastroenterol*. 2007;7:11.
35. Ruuska T, Vaajalahti P, Arajärvi P, et al. Prospective evaluation of upper gastrointestinal mucosal lesions in children with ulcerative colitis and Crohn's disease. *J Pediatr Gastroenterol Nutr*. 1994;19:181-186.
36. Abdullah BA, Gupta SK, Croffie JM, et al. The role of esophagogastroduodenoscopy in the initial evaluation of childhood inflammatory bowel disease: a 7-year study. *J Pediatr Gastroenterol Nutr*. 2002;35:636-640.
37. Tobin JM, Sinha B, Ramani P, et al. Upper gastrointestinal mucosal disease in pediatric Crohn disease and ulcerative colitis: a blinded, controlled study. *J Pediatr Gastroenterol Nutr*. 2001;32:443-448.
38. Goldblum JR, Appelman HD. Appendiceal involvement in ulcerative colitis. *Mod Pathol*. 1992;5:607-610.
39. Groisman GM, George J, Harpaz N. Ulcerative appendicitis in universal and nonuniversal ulcerative colitis. *Mod Pathol*. 1994;7:322-325.
40. Glickman JN, Bousvaros A, Farraye FA, et al. Pediatric patients with untreated ulcerative colitis may present initially with unusual morphologic findings. *Am J Surg Pathol*. 2004;28:190-197.
41. Washington K, Greenson JK, Montgomery E, et al. Histopathology of ulcerative colitis in initial rectal biopsy in children. *Am J Surg Pathol*. 2002;26:1441-1449.
42. Moum B, Vatn MH, Ekbohm A, et al. Incidence of inflammatory bowel disease in southeastern Norway: evaluation of methods after 1 year of registration. *Digestion*. 1995;56:377-381.

43. Stewenius J, Adnerhill I, Ekelund G, et al. Ulcerative colitis and indeterminate colitis in the city of Malmö, Sweden. A 25-year incidence study. *Scand J Gastroenterol.* 1995;30:38-43.
44. Riegler G, Arimoli A, Esposito P, et al. Clinical evolution in an outpatient series with indeterminate colitis. *Dis Colon Rectum.* 1997;40:437-439.
45. Geboes K, Colombel JF, Greenstein A, et al. Indeterminate colitis: a review of the concept-what's in a name? *Inflamm Bowel Dis.* 2008;14:850-857.
46. Hildebrand H, Fredrikzon B, Holmquist L, et al. Chronic inflammatory bowel disease in children and adolescents in Sweden. *J Pediatr Gastroenterol Nutr.* 1991;13:293-297.
47. Mamula P, Telega GW, Markowitz JE, et al. Inflammatory bowel disease in children 5 years of age and younger. *Am J Gastroenterol.* 2002;97:2005-2010.
48. Henriksen M, Jahnsen J, Lygren I, et al. Change of diagnosis during the first five years after onset of inflammatory bowel disease: results of a prospective follow-up study (the IBSEN study). *Scand J Gastroenterol.* 2006;41:1037-1043.
49. Austin GL, Herfarth HH, Sandler RS. A critical evaluation of serologic markers for inflammatory bowel disease. *Clin Gastroenterol Hepatol.* 2007;5:545-547.
50. Eliakim R, Fischer D, Suissa A, et al. Wireless capsule video endoscopy is a superior diagnostic tool in comparison to barium follow-through and computerized tomography in patients with suspected Crohn's disease. *Eur J Gastroenterol Hepatol.* 2003;15:363-367.
51. Guindi M, Riddell RH. Indeterminate colitis. *J Clin Pathol.* 2004;57:1233-1244.